



*This is an enhanced PDF from The Journal of Bone and Joint Surgery
The PDF of the article you requested follows this cover page.*

Long-Term Results of the Latarjet Procedure for the Treatment of Anterior Instability of the Shoulder

J. ALLAIN, D. GOUTALLIER and C. GLORION
J Bone Joint Surg Am. 1998;80:841-52.

This information is current as of October 24, 2010

Reprints and Permissions

Click here to [order reprints or request permission](#) to use material from this article, or locate the article citation on jbjs.org and click on the [Reprints and Permissions] link.

Publisher Information

The Journal of Bone and Joint Surgery
20 Pickering Street, Needham, MA 02492-3157
www.jbjs.org

Long-Term Results of the Latarjet Procedure for the Treatment of Anterior Instability of the Shoulder*

BY J. ALLAIN, M.D.†, D. GOUTALLIER, PH.D.‡, AND C. GLORION, PH.D.‡, CRETEIL, FRANCE

Investigation performed at the Department of Orthopaedics, Hôpital Henri Mondor, Creteil

ABSTRACT: We performed ninety-five consecutive Latarjet procedures for the treatment of recurrent anterior instability of the shoulder between 1969 and 1983. In 1993, we retrospectively reviewed the clinical and radiographic results that were available for fifty-six patients (fifty-eight shoulders) who had been followed for an average of 14.3 years (range, ten to twenty-three years). The purpose of the study was to determine the prevalence of glenohumeral osteoarthritis and the factors related to its development after the Latarjet procedure.

The procedure was performed for the treatment of recurrent anterior dislocation in fifty shoulders and painful recurrent anterior subluxation in eight. All patients had a radiographic evaluation (three anteroposterior radiographs, with the humerus in external, neutral, and internal rotation, and one lateral radiograph) before the operation and at the latest follow-up examination.

At the time of the latest follow-up, none of the patients had recurrent dislocation, six patients had apprehension with regard to possible dislocation, and one had occasional subluxation. According to the system of Rowe et al., fifty-one (88 per cent) of the fifty-eight shoulders had an excellent or good result; five (9 per cent), a fair result; and two (3 per cent), a poor result. Twenty-two shoulders had no glenohumeral osteoarthritis. Thirty-four shoulders had centered glenohumeral osteoarthritis (the humeral head remained in front of the center of the glenoid cavity), which was grade 1 in twenty-five shoulders, grade 2 in four, grade 3 in three, and grade 4 in two, and two shoulders had grade-4 eccentric glenohumeral osteoarthritis (the humeral head was more proximal than normal in relation to the center of the glenoid cavity). Postoperative grade-1 glenohumeral osteoarthritis, unlike the higher grades, had no effect on the function of the shoulder.

Two different procedures are used frequently in France for the treatment of recurrent anterior instability of the shoulder: the capsulolabral and ligament reconstruction described by Bankart¹ and the coracoid bone-

block transfer procedure described by Latarjet²⁴. The functional results after the Latarjet procedure are well documented and seem to be similar to those seen after the Bankart procedure^{8,9,17,18,28,34,38,39,42}. Although slightly better glenohumeral stabilization has been reported after the Latarjet procedure^{9,39,42}, pain and the development of glenohumeral osteoarthritis have been attributed to the technique.

The prevalence of glenohumeral osteoarthritis after operative stabilization of the shoulder has been analyzed in only a few series^{9,40,41}. The purpose of the present study was to determine the prevalence of glenohumeral osteoarthritis as well as the factors leading to its development after the Latarjet procedure. We performed ninety-five consecutive Latarjet procedures, and long-term clinical and radiographic results were available for fifty-eight shoulders (fifty-six patients). These shoulders were included in the study.

Materials and Methods

Selection of Patients

A Latarjet procedure was performed in forty-eight patients (fifty shoulders) who had recurrent anterior dislocation and in eight patients (eight shoulders) who had painful recurrent anterior subluxation. After radiographs had been made, thirty-five dislocations were reduced with the patient under general anesthesia. Fifteen dislocations were reduced by the patient. When they were first seen, all except two shoulders had a posterolateral cephalic notch on the humeral head (a Hill-Sachs lesion) or a lesion of the anterior aspect of the glenoid rim, or both.

The diagnosis was made on the basis of the clinical history and the radiographic and intraoperative findings. All patients had pain and apprehension when a force was applied to the hand while the shoulder was in abduction and external rotation. All had intra-articular evidence of anterior instability. None had preoperative posterior instability associated with the anterior instability.

Forty-three (74 per cent) of the shoulders were in male patients and fifteen (26 per cent) were in female patients. The average age was 27.5 years (range, fifteen to fifty-eight years) at the time of operative intervention and forty-two years (range, twenty-two to seventy-three years) at the latest follow-up examination. Forty-three shoulders (74 per cent) were on the dominant side. Two patients had had a previous Bankart procedure, which

*No benefits in any form have been received or will be received from a commercial party related directly or indirectly to the subject of this article. No funds were received in support of this study.

†Service de Chirurgie Orthopédique, Hôpital Henri Mondor, 51 Avenue du Maréchal de Lattre de Tassigny, 94010 Creteil CEDEX, France. E-mail address for Dr. Allain: jalortho@aol.com.

‡Service de Chirurgie Infantile, Hôpital Raymond Poincaré, 92380 Garches, France.

had failed. Two patients had an associated tear of the rotator cuff, which was diagnosed preoperatively in both patients. This diagnosis was confirmed by arthrography in one patient and by operative findings and later by postoperative arthrography in the other. The tears of the rotator cuff had not been repaired at the time of the index procedure.

All shoulders had a normal preoperative range of motion (equal to that on the contralateral, uninvolved side or, in the patients who had bilateral involvement, equivalent to the average range for the uninvolved shoulders in the entire series) except for the two that had a tear of the rotator cuff and the two that had had a previous Bankart procedure. The loss of external rotation of those four shoulders averaged 15 degrees.

Preoperatively, forty-nine patients (fifty-one shoulders; 88 per cent) had participated in sports. Each sport was classified with respect to the potential risk of injury of the shoulder. Type 1 consisted of non-impact sports (rowing, fencing, swimming the breaststroke, skin diving, gymnastics, langlauf [cross-country running or racing on skis], shooting, and sailing); type 2, high-impact sports (the martial arts with the exception of judo and karate, riding a bicycle or motorcycle, motocross, soccer, rugby with the exception of hooking [which involves overhead hitting movements and sudden stops by the player who stays in the middle of the scrum], water skiing, downhill skiing, parachuting, and equitation); type 3, overhead sports with hitting movements (climbing, weight lifting, shot putting, swimming the crawl or butterfly stroke, pole vaulting, figure skating, canoeing, pitching a ball, golf, field hockey, and tennis); and type 4, sports with overhead hitting movements and sudden stops (basketball, handball, volleyball, kayaking, goal keeping, water polo, rugby hooking, judo, karate, wrestling, hang gliding, wind surfing, diving, ice hockey, acrobatic dancing, and gymnastics performed either on the ground or on an apparatus).

Twenty-three patients (twenty-four shoulders; 41 per cent) participated in a type-4 sport; thirteen patients (fourteen shoulders; 24 per cent), in a type-3 sport; twelve patients (twelve shoulders; 21 per cent), in a type-2 sport; and one patient (one shoulder; 2 per cent), in a type-1 sport. Eight patients (eight shoulders; 14 per cent) competed on a national level, twenty-one patients (twenty-three shoulders; 40 per cent) competed on a regional or local level, and twenty patients (twenty shoulders; 34 per cent) engaged in a recreational sport.

The Latarjet procedure was performed in ninety-three patients (ninety-five shoulders) between 1969 and 1983. Thirty-six patients (thirty-six shoulders) were lost to follow-up. The remaining fifty-seven patients (fifty-nine shoulders) were contacted in 1993, but one of them declined to have a clinical and radiographic evaluation. Thus, fifty-six patients (fifty-eight shoulders) were included in the study. The patient who declined to be evaluated responded to a questionnaire,

on which he indicated that he had not had recurrent dislocation or pain.

Operative Technique

The operative technique provides dual glenohumeral stabilization. First, the anterior aspect of the glenoid rim is extended by transfer of the coracoid bone block. Second, anterior displacement of the humeral head is prevented during abduction because the coracobrachialis muscle, which is attached to the coracoid transfer, holds the subscapularis muscle in a distal position.

An osteotomy of the coracoid process was performed through a deltopectoral approach. The subscapularis was transected at the musculotendinous junction. From 1969 through 1980, the subscapularis was completely transected (thirty-eight shoulders). Beginning in 1981, only the middle third of the subscapularis was transected (eighteen shoulders). (The extent of the transection was unspecified in two shoulders.) After the capsule was opened, cortical bone on the inferior aspect of the coracoid process and on the anterior aspect of the glenoid rim was drilled to the cancellous bone. The coracoid transplant was fixed, in a horizontal position, to the inferior portion of the anterior aspect of the scapular neck so that the transplant was level with the anterior part of the glenoid rim. Two screws were used to fix the coracoid graft; both were driven into the posterior part of the scapular neck. An overlap suture was used in eighteen of the thirty-eight shoulders that had complete transection of the subscapularis, an edge-to-edge suture was used in eighteen, and the type of suture was unspecified in two. An edge-to-edge suture was used in the eighteen shoulders that had a transection of only the middle third of the subscapularis. The type of transection of the subscapularis and the type of suture were not specified for two shoulders.

Postoperative Management

The upper limb stayed at the side during the first postoperative week. The patients were then instructed by the surgeon to perform active forward elevation and abduction of the shoulder. Twenty-five days postoperatively, the patients began progressive external rotation of the shoulder.

Clinical Evaluation

All patients were examined by the same clinician (J. A.), who did not perform the operations. The examination included an assessment of the range of motion, pain, laxity, participation in sports activity, functional result, and strength, according to the system of Rowe et al.³⁴ and that of Constant and Murley⁷.

Radiographic Evaluation

Three anteroposterior radiographs with the humerus in external, neutral, and internal rotation and a lateral radiograph of the glenoid labrum as described



FIG. 1

Photograph showing the technique for making the radiograph of the glenoid labrum, which was used to diagnose a pseudarthrosis of the coracoid graft.

by Bernageau and Patte³⁴ (Figs. 1 and 2) were made preoperatively and at the latest follow-up evaluation. The lateral radiograph was useful in the diagnosis of pseudarthrosis of the coracoid graft. After a Latarjet procedure, it is not possible to analyze the inferior aspect of the glenoid because of the coracoid graft. Therefore, using a modification of the system of Samilson and Prieto³⁵, we evaluated glenohumeral osteoarthritis on the basis of the size of the inferior humeral exostosis. The glenohumeral osteoarthritis was classified as grade 1 when the exostosis was between one and three millimeters in height, grade 2 when it was between four and seven millimeters, or grade 3 when it was more than seven millimeters. Grade 4 was assigned if there was narrowing of the glenohumeral joint and sclerosis. The glenohumeral osteoarthritis also was characterized as eccentric if the humeral head was more proximal than normal in relation to the center of the glenoid cavity, and it was defined as centered if the humeral head remained in front of the center of the glenoid cavity.

The position of the coracoid graft was assessed on the anteroposterior radiographs by superimposing the anterior and posterior aspects of the glenoid rim (Fig. 3). The position was considered to be perfect when the lateral part of the coracoid graft was at the same level as the glenoid rim or less than five millimeters medial to it. The graft was considered to be too lateral when it projected on the articular cartilage, and it was considered to be too medial when it projected at least five millimeters medial to the glenoid rim. The position of the coracoid graft also was assessed according to its height in relation to the glenoid equator. The position was considered to be correct when the superior edge of

the coracoid graft was either on the same level as or just inferior to the glenoid equator.

All radiographs made preoperatively and at the latest follow-up examination were analyzed independently by two of us (D. G. and J. A.). A computed tomography scan was made of fifteen shoulders, and we compared the results on the scan with those on the standard radiographs. In each instance, the placement of the coracoid

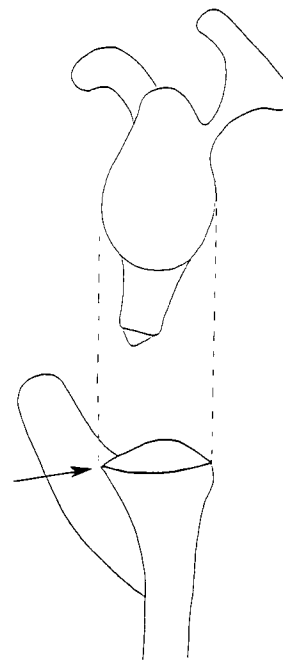


FIG. 2

Drawing showing the radiographic projection of the anterior aspect of the glenoid rim (arrow).

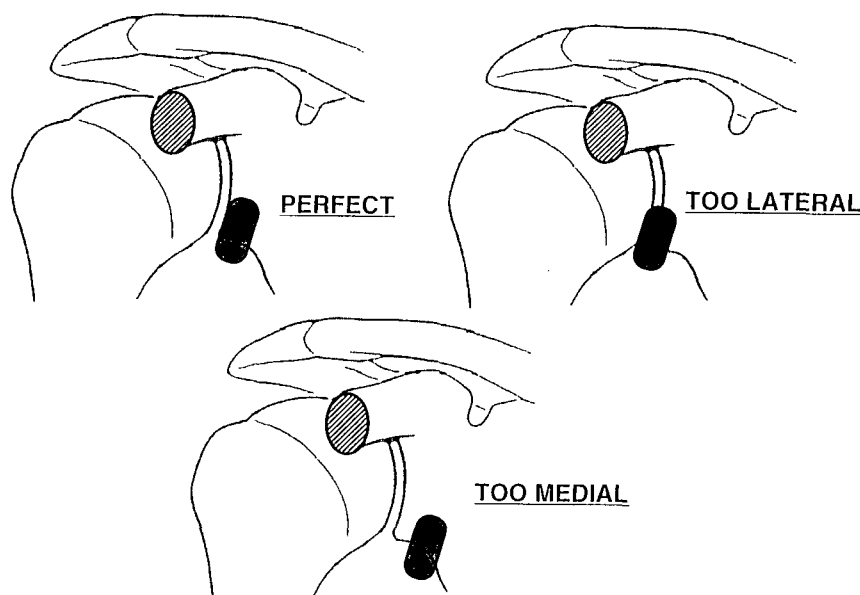


FIG. 3

Drawings showing the correct and incorrect positions of the coracoid graft.

graft seen on the standard radiographs corresponded with that seen on the computed tomography scan.

Statistical analysis was performed with use of the chi-square test and the analysis of variance test. A value of $p < 0.05$ was considered to be significant.

Results

Clinical Results

The average duration of follow-up was 14.3 years (range, ten to twenty-three years). According to the system of Rowe et al.³⁴, thirty-seven shoulders (64 per cent) had an excellent result; fourteen (24 per cent), a good result; five (9 per cent), a fair result; and two (3 per cent), a poor result. The average score according to the system of Constant and Murley⁷ was 84 points for the involved shoulder compared with 93 points for the contralateral, uninvolved shoulder. The average score for strength according to the system of Constant and Murley was 16 points (sixteen pounds [7.2 kilograms]) (range, 7 to 26 points) for the involved shoulder and 19 points (range, 8 to 26 points) for the contralateral, uninvolved shoulder.

Complications

Five complications occurred in four patients (7 per cent). Three infections developed after the operation. One of them resolved after operative drainage five days postoperatively. Another, which was diagnosed at fourteen months, resolved after operative drainage and removal of the screws. The third infection, which developed in the patient who had sustained an intra-articular radiating fracture of the glenoid during the osteotomy of the coracoid process, resolved after antibiotic therapy. In addition, a frozen shoulder developed in a psychiatric patient who had declined postoperative rehabilitation.

Two months postoperatively, a humeral fracture was sustained during manipulation of the shoulder with the patient under general anesthesia.

Stability

None of the patients had recurrent dislocation. One patient (2 per cent) reported a feeling of persistent instability and occasional subluxation. However, the instability was not confirmed at the clinical examination as the shoulder had normal anterior laxity and a negative apprehension sign. Six shoulders (10 per cent) caused subjective apprehension, but only one had a positive apprehension sign and none had abnormal anterior laxity during the clinical examination. Fifty-one (88 per cent) of the shoulders were reported to be stable by the patient, and all had normal laxity on physical examination.

Pain

Five shoulders (9 per cent) caused daily pain, fifteen (26 per cent) caused pain during exercise, and thirty-eight (66 per cent) caused no pain.

Range of Motion

External rotation, with the arm at the side and with 90 degrees of abduction, was an average (and standard deviation) of 63 ± 14 degrees (range, 30 to 95 degrees) on the contralateral, uninvolved side and an average of 42 ± 17 degrees (range, 10 to 80 degrees) on the side of the operation. External rotation of the shoulders that had an overlap suture in the subscapularis averaged 35 ± 12 degrees (range, 10 to 60 degrees), and that of the shoulders that had an edge-to-edge suture averaged 48 ± 18 degrees (range, 20 to 80 degrees). Therefore, external rotation of the involved shoulder was an aver-

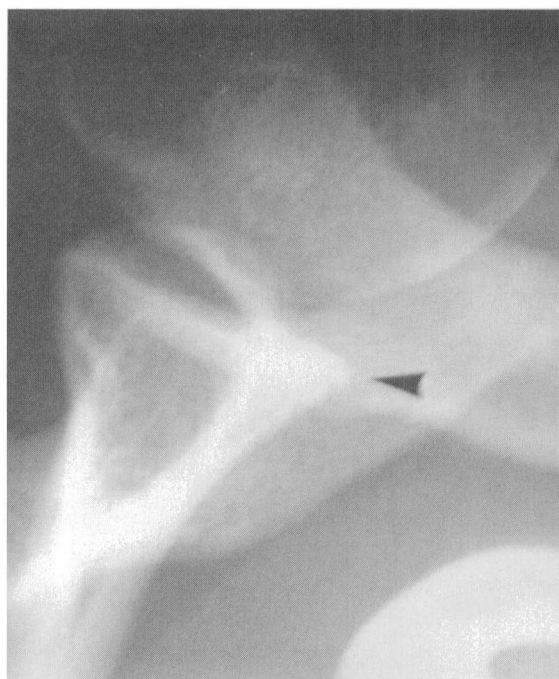


FIG. 4-A

Figs. 4-A, 4-B, and 4-C: Preoperative lateral radiographs showing the anterior aspect of the glenoid rim.

Fig. 4-A: Normal findings (arrowhead).

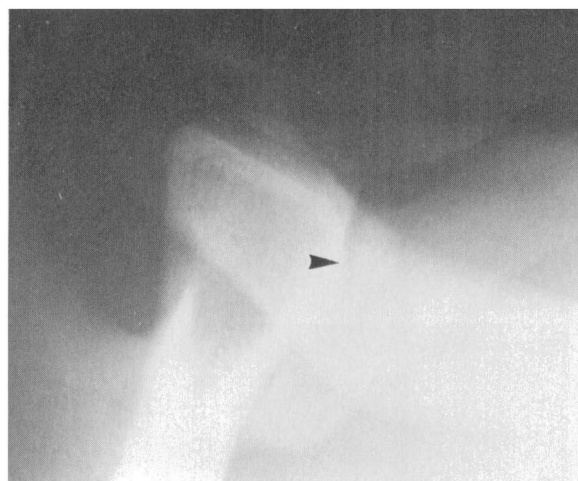


FIG. 4-B

Fracture (arrowhead).

age of 21 degrees less than that of the uninvolved shoulder. The eighteen shoulders that had the overlap suture in the subscapularis muscle lost an average of 29 degrees of external rotation, and the thirty-six that had the edge-to-edge suture lost an average of 15 degrees. Internal rotation was limited in nineteen shoulders (33 per cent). The type of anastomosis (overlap or edge-to-edge) of the subscapularis had no effect on internal rotation.

Return to Sports

Of the forty-nine patients (fifty-one shoulders) who had participated in sports preoperatively, forty (forty-one shoulders; 80 per cent) returned to the same sport

at the same level and five (six shoulders; 12 per cent) returned at a lower level. One patient (one shoulder; 2 per cent) was not able to return to sports, and three (three shoulders; 6 per cent) changed to a different sport after the operation. Of the sixteen patients (sixteen shoulders) who had competed in a type-4 sport (one that required hitting movements and sudden stops), eleven (eleven shoulders) returned at the same level, two (two shoulders) returned at a lower level, and three (three shoulders) changed to a different type of sports activity after the operation. Five of the six patients who had competed in a type-3 sport (one that required hitting movements but no sudden stops) returned at the same level and one returned at a lower level. The patients returned to the sports activities an average of four months after the operation.

Radiographic Results

Osseous Lesions

Preoperative radiographs demonstrated an osseous lesion in fifty-six shoulders (96 per cent). Fifty-two shoulders (90 per cent) had a lesion of the glenoid rim: twelve (21 per cent) had a fracture of the anterior aspect of the glenoid rim, thirty-eight (66 per cent) had erosion of the anterior aspect of the glenoid rim, and two (3 per cent) had both types of lesions (Figs. 4-A, 4-B, and 4-C). Fifty-two shoulders (90 per cent) had a posterosuperior defect of the humeral head (a Hill-Sachs lesion).

Coracoid Graft

The position of all coracoid grafts was either at the same level as or just inferior to the glenoid equator.

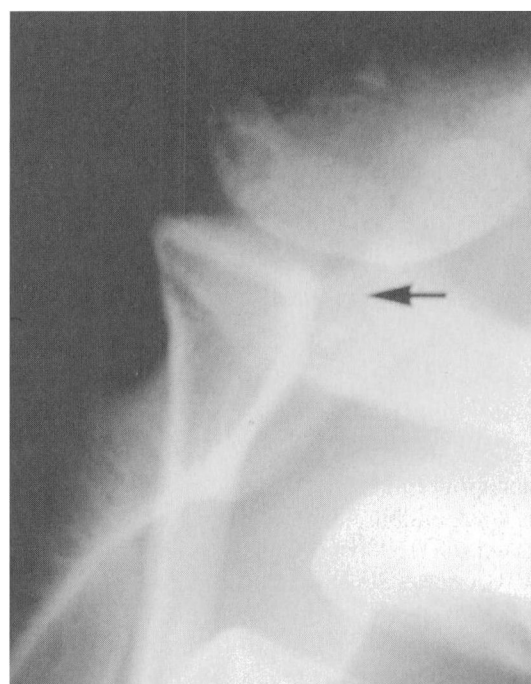


FIG. 4-C

Erosion (arrow).

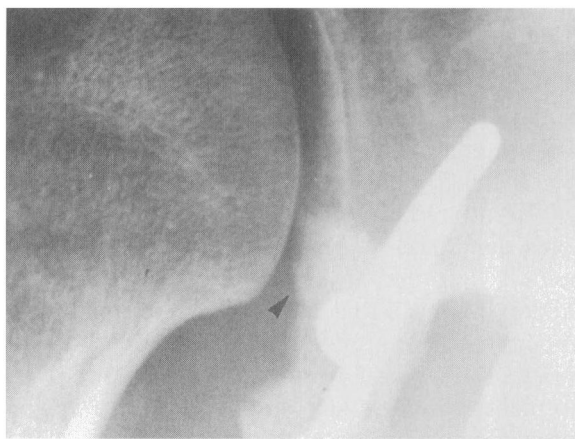

FIG. 5

Radiograph showing excessively lateral placement of the coracoid graft (arrowhead).

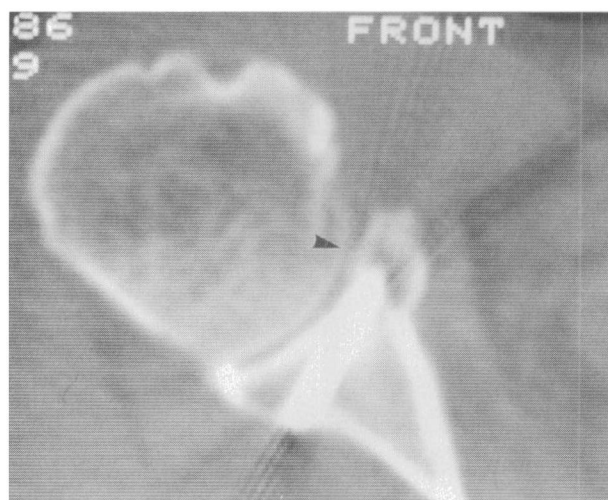


FIG. 6

Computed tomography scan showing excessively lateral placement of the coracoid graft (arrowhead).

With respect to the glenoid rim, the position of the graft was considered to be perfect in twenty-four shoulders (41 per cent), too lateral in thirty-one (53 per cent), and too medial in three (5 per cent) (Figs. 5, 6, and 7). At the time of the latest follow-up, two shoulders (3 per cent) had a non-union of the transferred coracoid process and ten shoulders (17 per cent) had partial osteolysis of the transplant.

Glenohumeral Osteoarthritis

Preoperatively, eleven (20 per cent) of fifty-four shoulders for which a review of the preoperative radiographs was possible had grade-1 glenohumeral osteoarthritis. At the latest follow-up examination, twenty-two shoulders (38 per cent) had no evidence of osteoarthritis (grade 0); twenty-five shoulders (43 per cent) had grade-1 glenohumeral osteoarthritis; four (7 per cent), grade-2; three (5 per cent), grade 3; and four (7 per cent), grade-4. Of the four grade-4 osteoarthrotic lesions, two were eccentric. Both were in shoulders that

had had a preoperative tear of the rotator cuff (Fig. 8).

Of twenty-three shoulders that had a radiographic evaluation in an earlier study²² (performed in 1986), four had grade-3 or 4 glenohumeral osteoarthritis at the time of the latest follow-up, in 1993. In each shoulder, the glenohumeral osteoarthritis had worsened compared with the 1986 radiographic findings, which had demonstrated grade-0 osteoarthritis in one shoulder, grade-2 in two, and grade-3 in one. (Three of these four shoulders had had grade-1 glenohumeral osteoarthritis preoperatively, and the fourth had had grade-0.) Only one of the three shoulders that had had grade-2 osteoarthritis in 1986 had the same grade at the time of the latest follow-up. Of the nineteen shoulders that had had grade-0 or grade-1 glenohumeral osteoarthritis in 1986, eight-

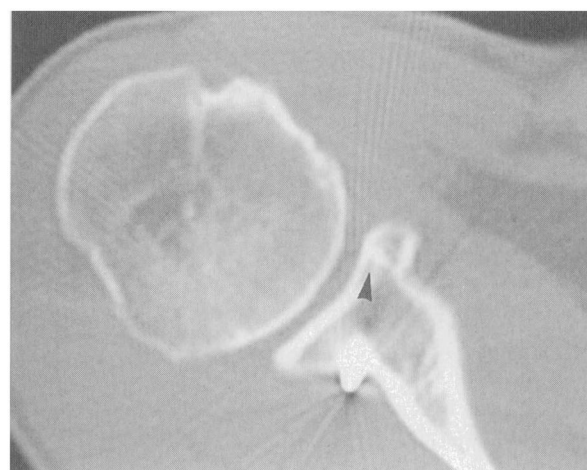

FIG. 7

Computed tomography scan showing perfect placement of the coracoid graft (arrowhead).

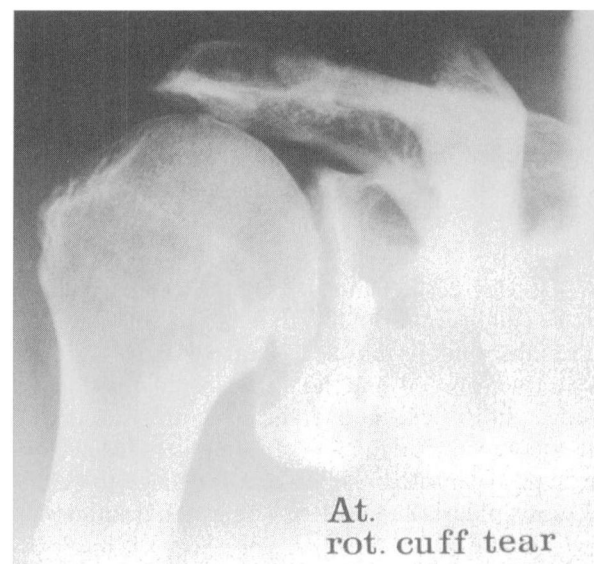

FIG. 8

Radiograph, made at the most recent follow-up evaluation, showing eccentric grade-4 glenohumeral osteoarthritis in a shoulder that had a preoperative tear of the rotator cuff.

TABLE I
FUNCTIONAL SCORE OF THE FIFTY-EIGHT SHOULDERS AT THE LATEST FOLLOW-UP EVALUATION

Grade of Glenohumeral Osteoarthritis	No. of Shoulders	Score According to System of Rowe et al. ³⁴ (points)			Global Score According to System of Constant and Murley ⁷ (points)
		Overall	Range of Motion	Function	
0	22 (38%)	90	15	28	82
1	25 (43%)	91	15	29	88
2	4 (7%)	89	10	29	91
3	3 (5%)	70	6.7	13.5	84
4	4 (7%)	61	7.5	14	63

teen did not have worsening of the osteoarthritis. One had worsening (to grade 3), as already mentioned.

Functional and Radiographic Analysis

The three shoulders that had had a postoperative infection had glenohumeral osteoarthritis at the latest follow-up examination. Grade-4 glenohumeral osteoarthritis had developed in the shoulder that had had an infection associated with an intraoperative radiating fracture of the glenoid. The score according to the system of Rowe et al.³⁴ was 80 points, and the global score according to the system of Constant and Murley⁷ was 76 points. The shoulder that had had an additional procedure for the treatment of a delayed infection fourteen months after the operation had a satisfactory result twelve years after the index operation: the score according to the system of Rowe et al. was 75 points, the global score according to the system of Constant and Murley was 83 points, and the shoulder had grade-1 glenohumeral osteoarthritis. The shoulder that had had an early revision operation for the treatment of an acute postoperative infection had poor functional and radiographic results: the score according to the system of Rowe et al. was 25 points, the global score according to the system of Constant and Murley was 51 points, and the shoulder had grade-4 glenohumeral osteoarthritis. Therefore, all of the infections resolved after treatment but not without considerable morbidity.

The frozen shoulder that had sustained a humeral fracture during manipulation had grade-3 glenohumeral osteoarthritis and a poor functional result (a score of 50 points according to the system of Rowe et al.³⁴ and a global score of 20 points according to the system of Constant and Murley⁷) at the time of the latest follow-up.

The function of both shoulders that had had an un-repaired tear of the rotator cuff preoperatively was fair and the radiographic result was poor (a score of 65 points for each according to the system of Rowe et al.³⁴ and a global score of 73 and 69 points according to the system of Constant and Murley⁷).

The two shoulders that had a pseudarthrosis and the ten that had partial osteolysis of the coracoid graft had

no impairment of function. These shoulders were as stable as those that did not have a pseudarthrosis or osteolysis. However, no conclusion could be made about this finding because of the limited number of shoulders that had a pseudarthrosis and the absence of substantial osteolysis of the coracoid graft.

We detected a significant association between the degree of postoperative glenohumeral osteoarthritis and the functional scores according to the systems of Constant and Murley⁷ ($p = 0.0001$) and Rowe et al.³⁴ ($p = 0.0001$) at the most recent follow-up evaluation (Table I). Grade-2 glenohumeral osteoarthritis was associated with a loss of motion. However, we found that function was not affected by postoperative grade-1 glenohumeral osteoarthritis (Fig. 9), a finding that has been confirmed by other studies^{35,41}. As none of the scores for the different parameters of function, according to the systems of Constant and Murley as well as Rowe et al., was affected by grade-1 glenohumeral osteoarthritis, we distinguished between the forty-seven shoulders that had postoperative centered glenohumeral osteoarthritis (grades 0 and 1) and the nine that had symptomatic centered glenohumeral osteoarthritis (grades 2, 3, and 4).

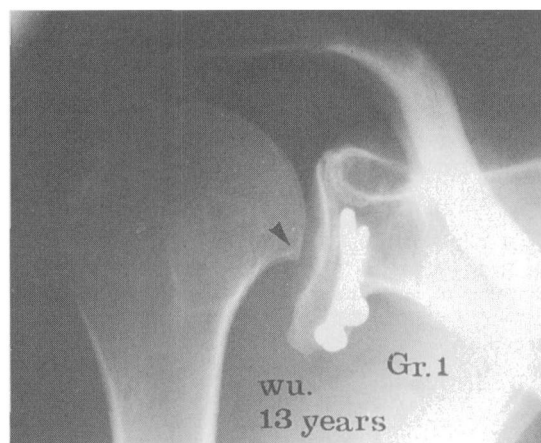


FIG. 9

Radiograph, made thirteen years postoperatively, showing grade-1 glenohumeral osteoarthritis (arrowhead). The shoulder had normal function.

TABLE II
ANALYSIS OF POSTOPERATIVE GLENOHUMERAL OSTEOARTHRISIS
WITH RESPECT TO THE POSITION OF THE CORACOID GRAFT*

Position of the Coracoid Transfer	Glenohumeral Osteoarthritis (no. of shoulders)	
	Grade 0 or 1	Grade 2, 3, or 4
Perfect	23	0
Too lateral	22	6
Too medial	1	0

*The analysis includes only the fifty-two shoulders without a complication or a tear of the rotator cuff.

Factors Associated with the Development of Symptomatic Glenohumeral Osteoarthritis

Three factors (a tear of the rotator cuff, an intraoperative or postoperative complication, and too lateral placement of the coracoid graft) appeared to lead to symptomatic postoperative glenohumeral osteoarthritis. The two shoulders that had grade-4 eccentric glenohumeral osteoarthritis had had a preoperative tear of the rotator cuff, and one of them had had grade-1 glenohumeral osteoarthritis preoperatively. Symptomatic centered glenohumeral osteoarthritis developed in three of the four shoulders that had had an intraoperative or postoperative complication.

We conducted a separate analysis of the fifty-two shoulders that had not had a tear of the rotator cuff or an intraoperative or postoperative complication in order to study other factors that led to the development of osteoarthritis. We found that the placement of the coracoid graft was the most important factor in the development of postoperative glenohumeral osteoarthritis ($p = 0.0016$). Symptomatic centered glenohumeral osteoarthritis (grades 2, 3, and 4) developed in six shoulders that had too lateral placement of the coracoid graft (Table II). The other twenty-two shoulders that had too lateral placement of the graft as well as all twenty-three shoulders that had perfect placement of the graft and the one shoulder that had too medial placement of the graft had grade-0 or grade-1 glenohumeral osteoarthritis.

The second factor that we found to be significantly associated with the development of postoperative glenohumeral osteoarthritis was the type of preoperative

TABLE III
ANALYSIS OF POSTOPERATIVE GLENOHUMERAL OSTEOARTHRISIS
WITH RESPECT TO THE TYPE OF PREOPERATIVE INSTABILITY*

Preoperative Instability	Glenohumeral Osteoarthritis (no. of shoulders)			
	Grade 0	Grade 1	Grade 2	Grade 3
Recurrent dislocation	15 (34%)	24 (55%)	3 (7%)	2 (5%)
Painful recurrent subluxation	7	0	1	0

*The analysis includes only the fifty-two shoulders without a complication or a tear of the rotator cuff.

instability ($p = 0.02$). The shoulders that had had recurrent anterior dislocation preoperatively had a higher postoperative rate of glenohumeral osteoarthritis than the shoulders that had had painful recurrent anterior subluxation (Table III). Nevertheless, with the numbers available, we did not find an association between the number of preoperative dislocations (or the delay between the first dislocation and the operation) and glenohumeral osteoarthritis at the latest follow-up examination ($p = 0.35$).

Despite the predictions of other investigators¹⁴, we did not find that overlap suture of the subscapularis led to a significantly higher rate of glenohumeral osteoarthritis ($p = 0.70$). Moreover, we could detect no association between external rotation at the latest follow-up examination and glenohumeral osteoarthritis ($p = 0.60$). Nevertheless, the average range of motion was 45 degrees for the shoulders that had grade-0 or grade-1 glenohumeral osteoarthritis, 36 degrees for those that had grade-2, and 35 degrees for those that had grade-3.

With the numbers available for study, we could not detect a significant association between gender, the age at the time of the operation and at the latest follow-up examination, the presence or type of preoperative osseous lesions, osteolysis or pseudarthrosis of the coracoid graft, or the type of preoperative or postoperative participation in sports and the development of glenohumeral osteoarthritis.

Of the fifty-two shoulders that had no tear of the rotator cuff or postoperative complications, eight had had preoperative glenohumeral osteoarthritis. At the latest follow-up evaluation, symptomatic glenohumeral osteoarthritis had developed in two of the eight shoulders. Statistical analysis of this finding was not possible because of the small number of shoulders involved.

Discussion

The fifty-eight shoulders that had had a Latarjet procedure in the present report were followed clinically and radiographically for an average of 14.3 years (minimum, ten years). Our study differs from other studies of the treatment of recurrent anterior instability of the shoulder^{2,5,8,11,12,15,16,20,26,29,32-34,37,39,41-43} because, although some of these studies had an adequate duration of follow-up, many included observations that were made on the basis of a short follow-up^{12,34,41,43} and few included a systematic analysis of radiographs (Table IV).

Other investigators have found, and we confirmed, that transfer of the tip of the coracoid process provides reliable stabilization of the shoulder^{2,9,27,28,39}. The findings in our series also demonstrated that shoulders that are stabilized with this procedure function satisfactorily over time.

We believe that the Latarjet technique has a dual mechanism for maintaining glenohumeral stability. First, the reinforcement effect of the coracobrachialis muscle

TABLE IV
SUMMARY OF REPORTS ON GLENOHUMERAL OSTEOARTHROSIS AFTER A STABILIZATION PROCEDURE

Study	Technique	No. of Shoulders	Duration of Follow-up* (yrs.)	Glenohumeral Osteoarthritis† (no. of shoulders)	Description of Glenohumeral Osteoarthritis‡
Delaunay et al. ⁸ (1985)	Latarjet	35	5 (2-9)	6 (7%)	Slight
Vander Maren et al. ³⁹ (1993)	Latarjet	33	3.5 (1.5-12)	5 (15%)	Grade 1 (1) and grade 3 (4)
Huguet et al. ²⁰ (1996)	Latarjet	51	3.7 (1-NA)	17 (31%)	Grade 1 (13), grade 2 (3), and grade 3 (1)
Allain et al. (1998)	Latarjet	58	14.3 (10-23)	36 (62%)	
Barry et al. ² (1985)	Bristow	36	6 (2.5-10)	2 (6%)	Early degenerative change (2)
Hill et al. ¹⁵ (1981)	Bristow	107	4.9 (3-8.8)	2%	
Ferlic and Digiovine ¹¹ (1988)	Bristow	32	8 (3.5-14)	2 (6%)	Degenerative change (2)
Weaver and Derkash ⁴² (1994)	Bristow	47	NA (2-NA)	2 (4%)	
Hindmarsh and Lindberg ¹⁶ (1967)	Eden-Hybbinette	106	8.5 (2-17.5)	72%	Grade 2 or 3
Lindholm ²⁶ (1974)	Eden-Hybbinette	124	NA (2-28)	10 (8%)	"Prominent" changes in joint
Solonen and Rokkanen ³⁷ (1972)	Eden-Hybbinette	52	7.5 (1-16)	6 (11%)	
Paavolainen et al. ³² (1984)	Eden-Hybbinette	41	4 (1-7)	5 (12%)	
Rowe et al. ³⁴ (1978)	Bankart	124	6 (1-30)	0	
Weaver and Derkash ⁴² (1994)	Bankart	17	NA (2-NA)	1	Grade 1
Vander Maren et al. ³⁹ (1993)	Bankart	17	3.5 (1.5-12)	1	Grade 1
Gerber et al. ¹² (1988)	Trillat	52	6 (3-10)	31 (63%)	Grade 1 (20), grade 2 (8), and grade 3 (3)
Walch et al. ⁴¹ (1989)	Trillat	250	11.5 (2-30)	43%	Grade 1 (27%), grade 2 (13%), and grade 3 (3%)
Boni et al. ⁵ (1992)	Eden-Lange	37	15 (NA)	17%	
Melzer et al. ²⁹ (1986)	Lange	21	13.5 (NA)	57%	
Paavolainen et al. ³² (1984)	Putti-Platt	21	4 (1-7)	10%	
Weber et al. ⁴³ (1984)	Humeral rotation osteotomy	180	8 (2-13)	2 (1%)	
Rodriguez Merchan and Ortega ³³ (1994)	Magnuson-Stack	44	12 (6-17)	0	

*The values are given as the average, with the range in parentheses. NA = not available.

†The percentages were calculated by dividing the number of shoulders with osteoarthritis by the number of shoulders for which radiographs had been made. All of the shoulders in each series were not necessarily studied radiographically.

‡The numbers in parentheses indicate the number of shoulders.

is predominant with the arm in abduction. Second, the bone block used for reconstruction of the glenoid concavity is very effective at the end of the throwing movement as well as with low abduction of the arm²⁵. Lazarus et al.²⁵ described the importance of anatomical reconstruction of the glenoid concavity, especially in shoulders that have a defect in the bone, cartilage, or labrum; these findings are consistent with our experience with the treatment of glenohumeral instability.

The stabilization of the shoulder achieved by the Latarjet procedure allowed more than 80 per cent of our patients (forty-one of fifty-one shoulders) who had participated in sports preoperatively to return to the same level of activity postoperatively despite an average loss of 15 degrees of external rotation. If these patients had been pitchers, the 15-degree loss of exter-

nal rotation would have been a severe impairment. Indeed, Jobe et al.²¹, Collins and Wilde⁶, and Lombardo et al.²⁷ strongly recommended that pitchers return to their sport only when the shoulder had been perfectly stabilized and complete external rotation had been recovered. The average loss of external rotation is the same after most of the different operative techniques. Except in the series reported by Rowe et al.³⁴, the Bankart procedure has led to a loss of external rotation of less than 15 degrees^{9,10,30,39,42}. The Eden-Hybbinette procedure has caused a loss of approximately 15 degrees of external rotation^{30,36,40}. Only humeral osteotomy^{19,23,43} and the Boytchev intervention¹³ has provided better external rotation.

The 7 per cent rate of complications (four of fifty-eight shoulders) in our study was lower than the rates

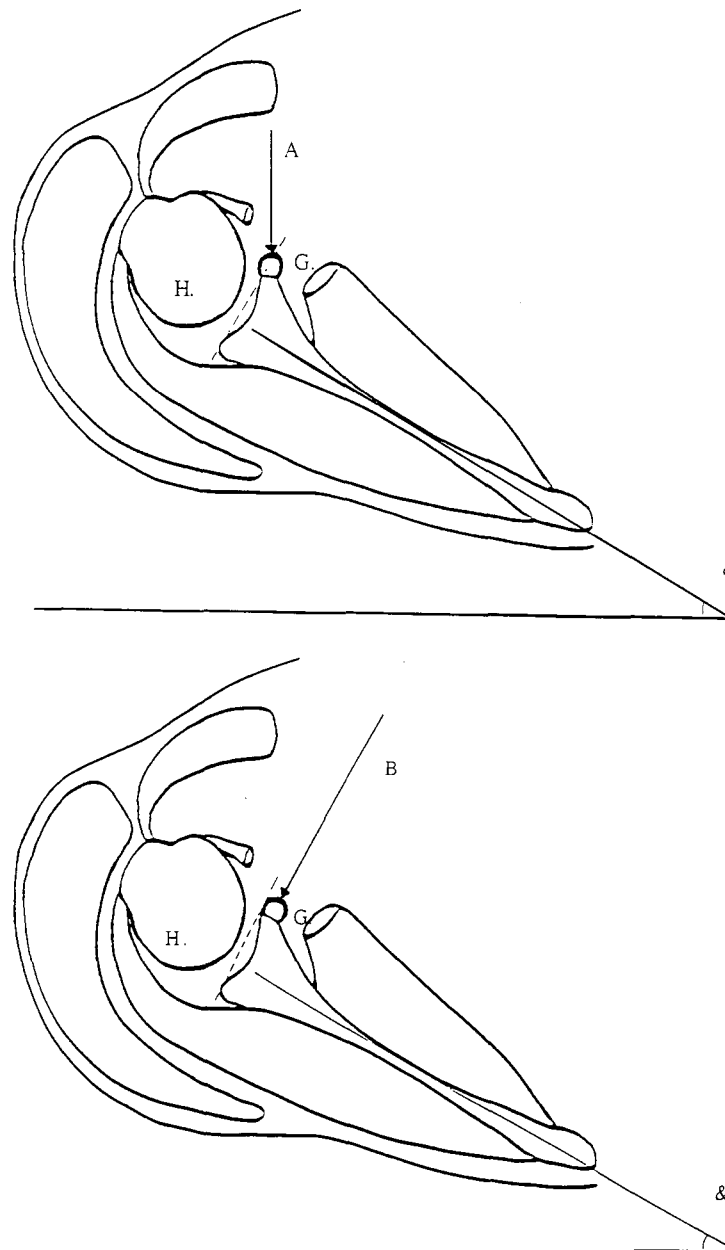


FIG. 10

Anatomical drawing illustrating the incorrect and correct placement of the coracoid graft. The graft is placed incorrectly when it is positioned on the anteroposterior axis (A). The graft is placed correctly when the axis of the graft is perpendicular to the plane of the scapula (B). H = humeral head, G = graft, and & = 30-degree angle of the scapula with the frontal plane.

reported in other studies of the Bristow-Latarjet procedure^{11,31,38,42,44,45}. Four shoulders had five complications, which included three infections, a radiating fracture of the glenoid, and a frozen shoulder. Secondary operative intervention was needed to treat the infection in two shoulders, and a pseudarthrosis developed in two shoulders. None of the shoulders had migration of the screws. We believe that the lower rate of complications in our study may be attributed to our use of two screws to fix the coracoid graft to the posterior aspect of the glenoid^{9,18,39,42} and to provide good compression.

The large number of shoulders (thirty-one) in which the coracoid graft was placed too laterally attests to the

difficulty of this operation. Considerable attention must be paid to operative technique. The operative view of the anterior aspect of the glenoid rim must be perfect before the coracoid graft is fixed, and the surgeon must consider the 30-degree anterior obliquity of the scapula on the thoracic skeleton (Fig. 10). After fixation of the coracoid transfer, the placement must be verified. If the position is too lateral, the external part of the graft must be removed. Another option is to fix the graft more medially, even in an extra-articular position (as in the Bristow procedure). However, we agree with Lazarus et al.²⁵ that reconstruction of the glenoid concavity is necessary for stabilization of the shoulder.

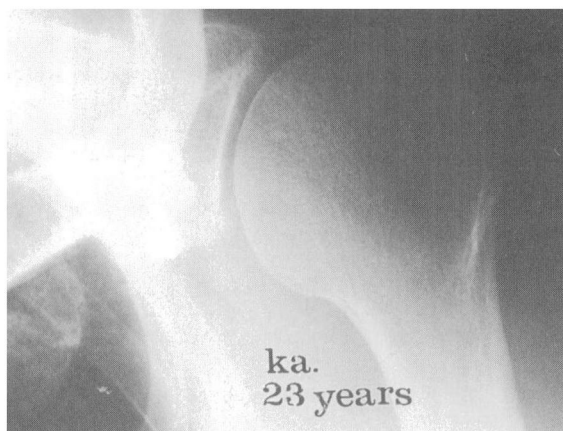


FIG. 11

Radiograph of a shoulder, made twenty-three years after the Latarjet procedure, showing no evidence of glenohumeral osteoarthritis.

Glenohumeral osteoarthritis developed in 58 per cent (thirty) of the fifty-two shoulders that had no tear of the rotator cuff and no postoperative complications (Table III). This is one of the highest rates of glenohumeral osteoarthritis reported after the Latarjet (or Bristow) procedure^{2,8,11,27,39,42} or the Bankart procedure^{34,39,42}. However, most (twenty-four) of the thirty shoulders had grade-1 osteoarthritis with no functional effect and without an increase in grade after more than ten years of follow-up. Moreover, our study had a longer duration of follow-up than most other studies and 20 per cent of the

shoulders in our series had had grade-1 glenohumeral osteoarthritis preoperatively.

We found, as have many other investigators^{9,18,28,38,39,42}, that too lateral placement of the coracoid graft led to postoperative glenohumeral osteoarthritis. This finding demonstrates the necessity for precise placement of the coracoid graft.

Our conclusions were made with caution because thirty-seven patients (thirty-seven shoulders) of the original ninety-three patients (ninety-five shoulders) either were lost to follow-up or declined to participate in the study. We found that the Latarjet procedure led to symptomatic glenohumeral osteoarthritis only in the shoulders that had had a preoperative tear of the rotator cuff or an intraoperative or postoperative complication. Thus, we recommend that shoulders be examined for a tear of the rotator cuff preoperatively and that the coracoid graft be placed with care taken to avoid excessively lateral placement. If these two recommendations are followed, it should be possible to improve upon the results in our series, in which the rate of perioperative or postoperative complications was 7 per cent. However, it should be noted that, after more than fourteen years of follow-up, none of the shoulders had recurrent dislocation and 81 per cent (forty-seven) had a normal radiographic appearance (Fig. 11) or only slight glenohumeral osteoarthritis with no notable functional effects.

References

1. Bankart, A. S. B.: The pathology and treatment of recurrent dislocation of the shoulder-joint. *British J. Surg.*, 26: 23-29, 1938.
2. Barry, T. P.; Lombardo, S. J.; Kerlan, R. K.; Jobe, F. W.; Carter, V. S.; Shields, C. L., Jr.; Yocum, L. A.; and Tibone, J. E.: The coracoid transfer for recurrent anterior instability of the shoulder in adolescents. *J. Bone and Joint Surg.*, 67-A: 383-387, March 1985.
3. Bernageau, J., and Patte, D.: Le profil glénoïdien. *J. Traumat. Sport*, 1: 15-19, 1984.
4. Bernageau, J., and Patte, D.: Examen radiologique des instabilités antérieures de l'épaule. *Radiologie J. Cepur*, 7: 165-173, 1987.
5. Boni, T.; Imhoff, A.; and Schreiber, A.: Klinischer und radiologischer Langzeitverlauf nach Eden-Lange-Operation bei habitueller vorderer Schulterluxation. *Zeitschr. Unfallchir. Versicherungsmed.*, 85: 117-126, 1992.
6. Collins, H. R., and Wilde, A. H.: Shoulder instability in athletics. *Orthop. Clin. North America*, 4: 759-774, 1973.
7. Constant, C. R., and Murley, A. H.: A clinical method of functional assessment of the shoulder. *Clin. Orthop.*, 214: 160-164, 1987.
8. Delaunay, C.; Lord, G.; Blanchard, J. P.; Marotte, J. H.; and Guillaumon, J. L.: Place actuelle du traitement des luxations récidivantes et des instabilités antérieures de l'épaule par l'intervention de Latarjet [English abstract]. *Ann. chir.*, 39: 293-304, 1985.
9. DeWaal Malefijt, J.; Ooms, A. J. A. M.; and Van Rens, T. J. G.: A comparison of the results of the Bristow-Latarjet procedure and the Bankart/Putti-Platt operation for recurrent anterior dislocation of the shoulder. *Acta Orthop. Belgica*, 51: 831-842, 1985.
10. Dickson, J. W., and Devas, M. B.: Bankart's operation for recurrent dislocation of the shoulder. *J. Bone and Joint Surg.*, 39-B(1): 114-119, 1957.
11. Ferlic, D. C., and Digiovine, N. M.: A long-term retrospective study of the modified Bristow procedure. *Am. J. Sports Med.*, 16: 469-474, 1988.
12. Gerber, C.; Terrier, F.; and Ganz, R.: The Trillat procedure for recurrent anterior instability of the shoulder. *J. Bone and Joint Surg.*, 70-B(1): 130-134, 1988.
13. Ha'eri, G. B.: Boytchev procedure for the treatment of anterior shoulder instability. *Clin. Orthop.*, 206: 196-201, 1986.
14. Hawkins, R. J., and Angelo, R. L.: Glenohumeral osteoarthritis. A late complication of the Putti-Platt repair. *J. Bone and Joint Surg.*, 72-A: 1193-1197, Sept. 1990.
15. Hill, J. A.; Lombardo, S. J.; Kerlan, R. K.; Jobe, F. W.; Carter, V. S.; Shields, C. L., Jr.; Collins, H. R.; and Yocum, L. A.: The modified Bristow-Helfet procedure for recurrent anterior shoulder subluxations and dislocations. *Am. J. Sports Med.*, 9: 283-287, 1981.
16. Hindmarsh, J., and Lindberg, A.: Eden-Hybbinette's operation for recurrent dislocation of the humeroscapular joint. *Acta Orthop. Scandinavica*, 38: 459-478, 1967.
17. Hovelius, L.; Thorling, J.; and Fredin, H.: Recurrent anterior dislocation of the shoulder. Results after the Bankart and Putti-Platt operations. *J. Bone and Joint Surg.*, 61-A: 566-569, June 1979.
18. Hovelius, L.; Korner, L.; Lundberg, B.; Åkermarck, C.; Herberts, P.; Wredmark, T.; and Berg, E.: The coracoid transfer for recurrent dislocation of the shoulder. Technical aspects of the Bristow-Latarjet procedure. *J. Bone and Joint Surg.*, 65-A: 926-934, Sept. 1983.
19. Huber, H. M.: Récidives d'instabilité et risques d'arthrose après ostéotomie sous-capitale de rotation de l'épaule [abstract]. *Fifth Congress of the European Society for Surgery of the Shoulder and the Elbow*, Würzburg, Germany, 1991.

20. Huguet, D.; Pietu, G.; Bresson, C.; Potaux, F.; and Letenneur, J.: Instabilité antérieure de l'épaule chez le sportif: à propos de 51 cas de stabilisation par intervention de Latarjet-Patte. *Acta Orthop. Belgica*, 62: 200-206, 1996.
21. Jobe, F. W.; Giangarra, C. E.; Kvitne, R. S.; and Glousman, R. E.: Anterior capsulolabral reconstruction of the shoulder in athletes in overhead sports. *Am. J. Sports Med.*, 19: 428-434, 1991.
22. Kooli, M.; Glorion, C.; DeLadoucette, A.; and Goutallier, D.: Technique et résultats de l'intervention de Latarjet dans les luxations récidivantes de l'épaule. Read at the annual meeting of the Société Tunisienne de Chirurgie Orthopédique et Traumatologique, Gammarth, Tunisia, June 11, 1990.
23. Kronberg, M., and Broström, L. A.: Osteotomy of the humerus to stabilize the shoulder joint [abstract]. *Fifth Congress of the European Society for Surgery of the Shoulder and the Elbow*, Würzburg, Germany, 1991.
24. Latarjet, M.: A propos du traitement des luxations récidivantes de l'épaule. *Lyon chir.*, 49: 994-997, 1954.
25. Lazarus, M. D.; Sidles, J. A.; Harryman, D. T., II; and Matsen, F. A., III: Effect of a chondral-labral defect on glenoid concavity and glenohumeral stability. A cadaveric model. *J. Bone and Joint Surg.*, 78-A: 94-102, Jan. 1996.
26. Lindholm, T. S.: Results of treatment for anterior recurrent dislocation of the shoulder joint with the Eden-Hybbinette operation. *Acta Orthop. Scandinavica*, 45: 508-517, 1974.
27. Lombardo, S. J.; Kerlan, R. K.; Jobe, F. W.; Carter, V. S.; Blazina, M. E.; and Shields, C. L., Jr.: The modified Bristow procedure for recurrent dislocation of the shoulder. *J. Bone and Joint Surg.*, 58-A: 256-261, March 1976.
28. Matton, D.; Van Looy, F.; and Geens, S.: Recurrent anterior dislocations of the shoulder joint treated by the Bristow-Latarjet procedure. Historical review, operative technique and results. *Acta Orthop. Belgica*, 58: 16-22, 1992.
29. Melzer, C.; Krödel, A.; and Refior, H. J.: Klinische und röntgenologische Spätergebnisse nach operativer Behandlung der habituellen Schulterluxation in der Technik nach M. Lange. *Zeitschr. Orthop.*, 124: 703-706, 1986.
30. Morrey, B. F., and Janes, J. M.: Recurrent anterior dislocation of the shoulder. Long-term follow-up of the Putti-Platt and Bankart procedures. *J. Bone and Joint Surg.*, 58-A: 252-256, March 1976.
31. O'Driscoll, S. W., and Evans, D. C.: Long-term results of staple capsulorrhaphy for anterior instability of the shoulder. *J. Bone and Joint Surg.*, 75-A: 249-258, Feb. 1993.
32. Paavolainen, P.; Björkenheim, J. M.; Ahovuo, J.; and Slätis, P.: Recurrent anterior dislocation of the shoulder. Results of Eden-Hybbinette and Putti-Platt operations. *Acta Orthop. Scandinavica*, 55: 556-560, 1984.
33. Rodriguez Merchan, E. C., and Ortega, M.: The Magnuson-Stack operation for recurrent anterior dislocation of the shoulder. A long-term follow up of 44 operations. *Internat. Orthop.*, 18: 356-358, 1994.
34. Rowe, C. R.; Patel, D.; and Southmayd, W. W.: The Bankart procedure. A long-term end-result study. *J. Bone and Joint Surg.*, 60-A: 1-16, Jan. 1978.
35. Samilson, R. L., and Prieto, V.: Dislocation arthropathy of the shoulder. *J. Bone and Joint Surg.*, 65-A: 456-460, April 1983.
36. Schroder, H. A., and Fristed, P. B.: Recurrent dislocation of the shoulder. The Alvick modification of the Eden-Hybbinette operation. *Acta Orthop. Scandinavica*, 56: 396-399, 1985.
37. Solonen, K. A., and Rokkanen, P.: The results of operative treatment for recurrent dislocation of the gleno-humeral joint. *Acta Orthop. Scandinavica*, 43: 101-108, 1972.
38. Torg, J. S.; Balduini, F. C.; Bonci, C.; Lehman, R. C.; Gregg, J. R.; Esterhai, J. L.; and Hensal, F. J.: A modified Bristow-Helfet-May procedure for recurrent dislocation and subluxation of the shoulder. Report of two hundred and twelve cases. *J. Bone and Joint Surg.*, 69-A: 904-913, July 1987.
39. Vander Maren, C.; Geulette, B.; Lewalle, J.; Mullier, J.; Autrique, J.-C.; Thiery, J.; and Deneufbourg, J.: Butée coracoïdienne selon Latarjet versus opération de Bankart. Étude comparative des résultats à propos de 50 cas. *Acta Orthop. Belgica*, 59: 147-155, 1993.
40. Vastamäki, M.; Antti-Poika, I.; Viljakka, T.; and Landtman, M.: Eden-Hybbinette procedure. Long term results [abstract]. *Fifth Congress of the European Society for Surgery of the Shoulder and the Elbow*, Würzburg, Germany, 1991.
41. Walch, G.; Neyret, P.; Charret, P.; Pietropaoli, H.; and DeJour, H.: L'opération de Trillat pour luxation récidivante antérieure de l'épaule. Résultats à long terme de 250 cas avec un recul moyen de 11,3 ans. *Lyon chir.*, 85: 25-31, 1989.
42. Weaver, J. K., and Derkash, R. S.: Don't forget the Bristow-Latarjet procedure. *Clin. Orthop.*, 308: 102-110, 1994.
43. Weber, B. G.; Simpson, L. A.; and Hardegger, F.: Rotational humeral osteotomy for recurrent anterior dislocation of the shoulder associated with a large Hill-Sachs lesion. *J. Bone and Joint Surg.*, 66-A: 1443-1450, Dec. 1984.
44. Young, D. C., and Rockwood, C. A., Jr.: Complications of a failed Bristow procedure and their management. *J. Bone and Joint Surg.*, 73-A: 969-981, Aug. 1991.
45. Zuckerman, J. D., and Matsen, F. A., III: Complications about the glenohumeral joint related to the use of screws and staples. *J. Bone and Joint Surg.*, 66-A: 175-180, Feb. 1984.